

Evaluation of Tissue Interaction and Orthodontic Tooth Movement Following Application of FDBA and DFDBA

Massoud Seifi¹ Nafise Shamloo^{2*} Meysam Mirzaei³

¹Professor, Dept. of Orthodontics, Dental School, Shahid Beheshti University of Medical Sciences, Tehran-Iran

^{2*}Corresponding Author: Assistant Professor, Dept. of Oral & Maxillofacial Pathology, Dental School, Shahid Beheshti University of Medical Sciences, Tehran- Iran.

E-mail: n_shamloo@yahoo.com

³Dentist

Abstract

Objective: The purpose of this study was to investigate the histologic interaction between two different allografts and first premolar root following orthodontic tooth movement.

Methods: This experimental study was conducted on 4 male dogs. In each dog, four defects were created at the mesial aspects of the maxillary and mandibular first premolars. The defects were filled with DFDBA or FDBA equally. NiTi closed coil with 150 gr force was used for mesial movement of the first premolar tooth. When the experimental teeth moved about halfway into the defects i.e. after nine weeks, the animals were sacrificed and the area of interest was harvested. The first premolar root and adjacent tissues were histologically evaluated. Tooth movements were analyzed using paired t-test.

Results: Study findings demonstrated that it was possible to move a tooth into a defect, filled with DFDBA or FDBA with the same rate of tooth movement. Mean tooth movement was 2.6 ± 0.11 mm in DFDBA and 2.4 ± 0.12 mm in FDBA. Apical root resorption occurred on the pressure sides in both groups.

Conclusion: These findings indicate that FDBA and DFDBA can be used as biocompatible bone substitutes for bone defects subjected to orthodontic tooth movement.

Key words: Orthodontic, Tooth movement, Bone, Allograft

Citation: Seifi M, Shamloo N, Mirzaei M. Evaluation of tissue interaction and orthodontic tooth movement following application of FDBA and DFDBA. *J Dent Sch* 2012;30(1):60-67

Received: 17.09.2011

Final Revision: 26.12.2011

Accepted: 07.01.2012

Introduction:

Secondary bone grafting has been successfully used in patients with cleft lip and cleft palate for stabilization of premaxilla, better support of nasal base, eruption of permanent canines, holding bone segments in place after expansion, reconstruction of alveolar ridge, bone regeneration along with implant placement, preventing ridge atrophy following extraction or causing orthodontic tooth movement into the bone defects (1).

Autogenous bone is a suitable bone graft material in such cases. However, considering the need for secondary surgery and its side effects and also risk of atrophy of the grafted bone and

limited amount of bone, various studies have been conducted to find other sources that can be used as bone graft material (2).

Several studies have investigated tooth movement in secondary grafts. For example, Feinberg (1989)(3), Zakir (1996)(4), Araujo (2001)(5), and Oltramari (2007)(2) used hydroxyapatite, calcium phosphate, Bio-Oss and xenogeneic graft as the secondary bone graft material in their studies, respectively.

Allografts are commonly used for reconstruction of bone defects. Allogenic bone is osseous tissue procured from another person from the same species that provides type I collagen for the recipient (5) and possesses the main organic constituents of bone. DFDBA (Demineralized

Freeze-Dried Bone Allograft) and FDBA (Freeze-Dried Bone Allograft) are the 2 main forms of allografts. FDBA has been extensively evaluated in humans and animals and its biologic compatibility and clinical efficacy have been confirmed (6, 7). DFDBA has been vastly studied in terms of inducing bone formation for treatment of periodontal lesions. Some comparative studies have reported the superiority of DFDBA in terms of having high osteogenic potential (8). Some others, however, believe in the superiority of FDBA (9) or have not found any difference between the two (10). Several clinical assessments performed by Mellonig et al. (1981)(8) demonstrated more than 50% bone formation in 67% of defects receiving FDBA and in 78% of those treated with FDBA along with autogenous bone blend. FDBA was considered as an osteoconductive material; whereas, DFDBA was considered an osteoinductive bone graft material. In-vitro studies have demonstrated that DFDBA has greater osteogenic potential than FDBA (11). Mellonig et al. (1981) in a histologic study on humans indicated periodontal regeneration and new attachment and bone formation in defects receiving DFDBA. They compared DFDBA with autogenous material in the calvaria of guinea pigs and found that they have similar osteogenic potentials (8).

These studies showed that application of DFDBA in periodontal lesions can significantly decrease probing depth and increase attachment level in the regenerated bone. Combination of DFDBA and GTR has also yielded successful results (12).

Cammack et al, in 2005 compared mineralized and demineralized freeze dried bone allografts for ridge and sinus augmentations in 93 patients and found no difference between the 2 groups in terms of bone formation (13). The aim of this study was to determine the effect of interaction of orthodontic tooth movement with 2 types of

allografts DFDBA and FDBA.

Methods:

The present experimental study was conducted on 16 quadrants (maxilla and mandible) of 4 male mixed-breed dogs aged 1-2 years and weighing 20-25 kg. Number of understudy samples was determined through evaluation of related previous studies and with the help of a statistician. Data were collected via observation and direct measurement of tooth movement.

Male adult dogs weighing 20-25 kg whose general and periodontal health had been confirmed and had intact and sound first premolar and canines were entered the study. In case of being sick or presence of periodontal disease in the first premolar or canine areas, the dog would be excluded from the study. Before the conduction of the scientific phases, the dogs were kept in the animal room of the small animal clinic of Tehran University, School of Veterinary Medicine for 2 weeks in similar conditions and were vaccinated. After completion of this time period, the dogs were anesthetized using 5 mg/kg ketamine 10% administered intravenously. After anesthesia induction, the oral cavity was carefully washed with physiological saline and chlorhexidine solution. After injection of local anesthetic (lidocaine along with epinephrine), a full thickness flap was made from the canine to the first premolar teeth (Figure 1).

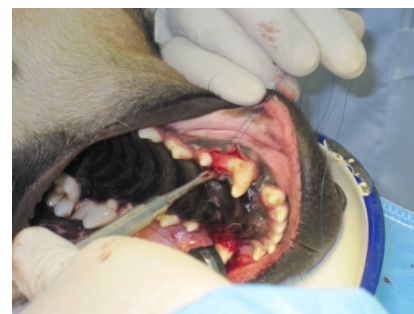

Figure 1- Full thickness flap

After primary penetration, a defect was created at the mesial aspect of the first premolar in each quadrant with a final diameter of $\frac{3}{4}$ mm and depth of 10 mm using an implant drill (Nobel biocare company, /LLC, USA). DFDBA and FDBA powders (CenoBone, HamanandSazBaft Co.) were mixed with the same amount of saline solution and prepared for insertion into the prepared holes. In 8 quadrants FDBA and in another 8 DFDBA were implanted. Thus, we were able to compare the right and left samples with each other and these two materials were placed equally in left and right defects. Tissue was sutured using 3-0 Nylon sutures (remained in the area for 10 days). The first premolar tooth was moved mesially using NiTi close coil with 9mm length (Ormco Co.) and 150 g force measured by force gauge (Figure 2).

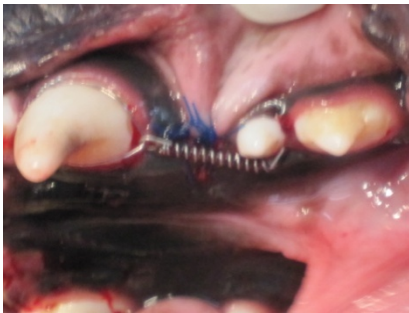

Figure 2- Causing orthodontic movement at the site

At the mesiogingival surface of the canine tooth crown, a slot was formed and NiTi closed coil was fixed at the slot using ligature wire. A similar groove was formed at the distogingival of the first premolar tooth and NiTi closed coil was attached to it after extension. The slots were then covered with light cure composite. The distance between the first premolar and canine was measured by a digital caliper (Cen-tech) with 0.001 inch precision and measurements were performed at 3 weeks intervals. These measurements were continued for 9 weeks. During the study period, the dogs were fed soft

moist food (Friskies). For prophylaxis and in order to prevent infection, 22 mg/kg cefazolin was administered IM every 8 hours for 3 days. In order to decrease post-op pain, 5 mg/kg tramadol was injected IM 30 min before the operation and every 12 hours post-operatively for 2 days. At the end, after deep anesthesia induction with ketamine 10%, the animals were sacrificed by injecting Magnesium sulfate. After separating the jaws, samples were placed in formalin 10% solution. The specimens were then stored in nitric acid for 10 days to become decalcified. After this time period, they were placed in 10% formalin for 24 hours and then for dehydration, the samples were placed for 90 min in 70% alcohol, 90 min in 80% alcohol, 150 min in 96% alcohol and 150 min in 100% alcohol in an orderly fashion. Then the specimens were stored for 2 h in Xylol and 8 to 18 hours in 56-67°C melting paraffin to become embedded. Paraffin embedded blocks were then cut by rotary microtome. Of each sample several 5 micron thickness slices were prepared mesiodistally. After cutting the slices, specimens were placed in dry heat sterilizer at 80-110°C for 30 min and then were H & E stained. Samples were examined under a light microscope (Nikon, E-400 Japan) in terms of presence of inflammation in the periodontium, reorganization of the arrangement of PDL fibers, root resorption, and interaction with the graft material. ANOVA statistical test was used to compare the rate of tooth movement.

Results:

Premolar teeth in both groups showed a mesial movement. Before sacrificing the dogs, the teeth were halfway towards the allograft material. Movement of first premolar was measured every 3 weeks. These measurements were continued for 9 weeks. Table 1 shows the mean rate of movement for the first premolar teeth at each measuring time.

Table 1- Mean tooth movement at each phase based on the group and the jaw

Time	Group	The jaw	Mean	Standard Deviation	Number
First phase	DFDBA	Maxilla	0.94	0.08	4
		Mandible	0.86	0.08	4
		Total	0.90	0.08	8
	FDBA	Maxilla	0.88	0.1	4
		Mandible	0.83	0.14	4
		Total	0.85	0.12	8
Second phase	DFDBA	Maxilla	0.98	0.06	4
		Mandible	0.86	0.03	4
		Total	0.92	0.08	8
	FDBA	Maxilla	0.79	0.07	4
		Mandible	0.79	0.07	4
		Total	0.79	0.06	8
Third phase	DFDBA	Maxilla	0.93	0.03	4
		Mandible	0.77	0.17	4
		Total	0.85	0.14	8
	FDBA	Maxilla	0.74	0.1	4
		Mandible	0.68	0.1	4
		Total	0.71	0.1	8
Total	DFDBA	Maxilla	0.95	0.06	12
		Mandible	0.83	0.1	12
		Total	0.89	0.1	24
	FDBA	Maxilla	0.80	0.1	12
		Mandible	0.77	0.12	12
		Total	0.78	0.11	24

Using three-way ANOVA, no significant difference was detected in terms of tooth movement at each phase of measuring or the jaw (maxilla or mandible) between the DFDBA and FDBA groups ($P=0.05$). Also, no difference was observed between the 2 groups in terms of total movement at the end of study using paired t-test. The mean tooth movement in the time period of 3 weeks was reported to be 0.89 ± 0.1 mm in DFDBA and 0.78 ± 0.11 mm in the FDBA group. Total movement of the first premolar in both groups of DFDBA and FDBA at the end of 9 weeks was almost similar and about 2.5 mm (2.6 ± 0.11 in DFDBA and 2.4 ± 0.21 in FDBA groups). Therefore, we can conclude that the first premolar moved 1.2 mm per month into the allograft material (Figure 1 and 2). Gingival tissue surrounding the first premolars had chronic inflammatory infiltration of lymphocytes and plasmacells. But the underlying bone had no sign of such inflammation. The two groups had many similarities histologically. The first

premolar in both groups had normal dentin and pulp tissue. Cementum had covered the root dentin surface almost completely. However, the apical one third in both groups had resorption lacunae with osteoclasts and showed mild root resorption (Figures 3 and 4)

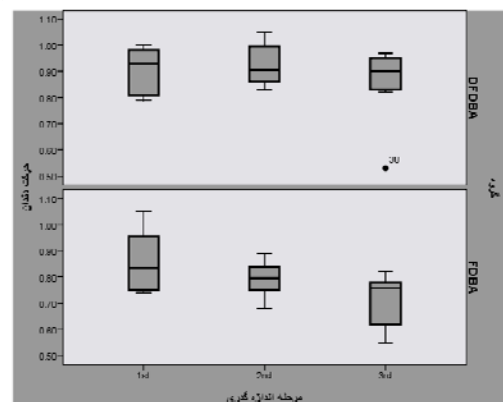


Figure 1- Box plot for 2 types of allografts showing the mean and standard deviation of movements

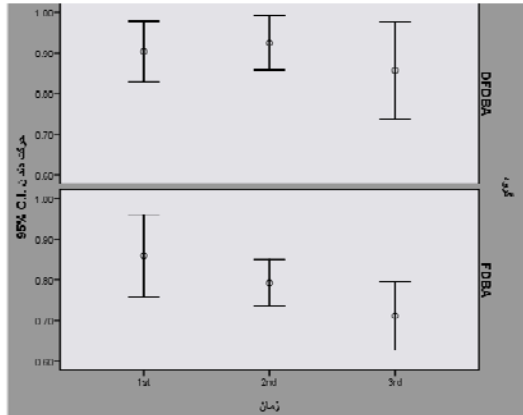


Figure 2- Error bar for comparison of mean with 95% confidence interval

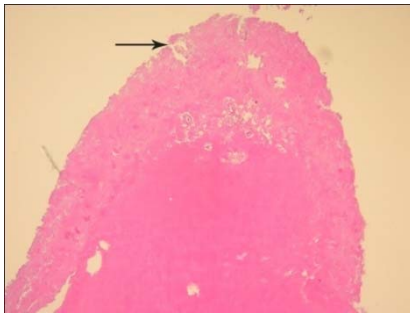


Figure 3- Root resorption at apical one third

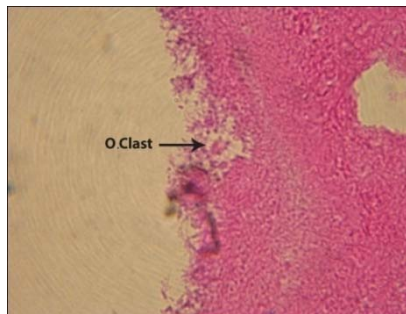


Figure 4: Osteoclast in a resorption lacuna

PDL was full of dense collagen fibers, cell rich connective tissue and randomly designed fibers.

At the distal of first premolar (tension area) collagen fibers and bone deposition were observed under tension. Particles of the allograft material were not present at this side. Along with bone deposition, collagen fibers and

fibroblasts were also present which were indicative of Sharpey's fibers' formation associated with bone deposition (Figure 5).

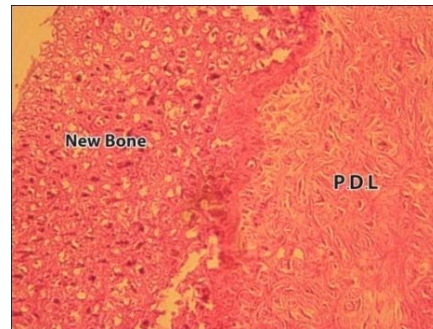


Figure 5- Collagen fibers under tension and bone deposition

At the mesial aspect of first premolar in the FDBA group, increased osteoblastic activity was observed at the center of the allograft and osteocytes were present in the lacunae (Figure 6). The newly formed bone had large osteocytic lacunae. The surrounding bone was normal with no inflammatory infiltration.

In the DFDBA, the central area was almost intact. At the margins of the newly formed bone, particles of DFDBA had participated in the process of osteogenesis (Figures 7 and 8). Macrophages were present around the allograft. The surrounding bone was normal without sequestration or inflammation.

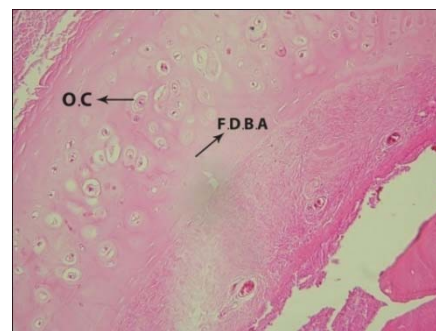

Figure 6- Osteogenesis and osteocytes surrounded by FDBA

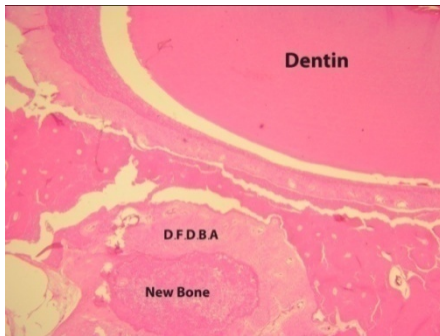

Figure 7- Osteogenesis around the DFDBA

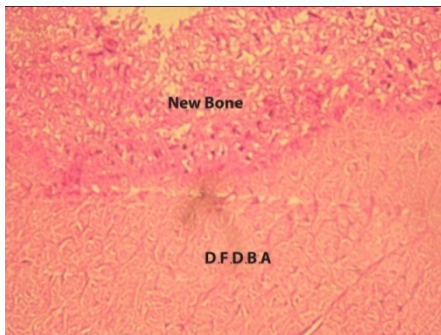


Figure 8- Osteogenesis around the DFDBA

Discussion:

This study showed that it is possible to move the tooth into a defect filled with allograft using orthodontic force. After applying the orthodontic force, teeth of both groups moved mesially at the rate of 1.2 mm per month which was similar in both groups. In previous studies like those of Wennstrom (1993)(14), Araujo (2001)(5) and Oltramari (2007)(2) dogs' teeth had been moved bodily. Rate of movement per month in the Gentech graft material was about 1 mm/month (2) which is similar to our study. Zakir (1996) reported the movement of 2 mm/month in tricalcium phosphate ceramics. This rate may be due to the fact that they moved a central incisor.

Measurements performed after each time period (3 weeks) indicated the continuous movement of the tooth into the allograft. The mean tooth movement at different phases of measurements

was close to each other which can be due to the small overall movement distance (2.5 mm).

In both groups, a little resorption was observed at apical one third which is in accord with what was observed in other studies (2, 5, 14). This finding can approve the theory that root resorption may be an iatrogenic consequence of orthodontic tooth movement and apical resorption is an idiopathic complication of this treatment. Histologic studies demonstrated that this amount of root resorption does not affect the integrity of the tooth.

At the mesial side (pressure), grafted biomaterial did not interfere with the tooth movement and on the other hand at the tension side bone deposition occurred and no trace of grafted biomaterial was found in this area. This finding is in agreement with the results of Araujo (2001)(5) and Zakir (1996)(4) regarding a Bio-Oss graft.

Piattelli et al, (1996)(9) histologically evaluated DFDBA and FDBA and reported that in the FDBA group, even the particles that were farthest from the host bone participated in the process of osteogenesis whereas, in DFDBA only the particles that were near the host bone participated in the mineralization processes and those farther away than the host bone were surrounded by collagen fibers and were not involved in the process of bone formation. Therefore, it seems that osteoconductive effect of FDBA is superior to that of DFDBA.

They believed the reason to be the fact that DFDBA matrix is first affected by the acidic proteins adjacent to the bone or osteoblasts and undergoes some biochemical changes. Since the penetration depth of these proteins is limited, complete mineralization does not occur at the center of DFDBA. At the second phase, this altered matrix undergoes heterogeneous nucleation.

In the present study, active osteogenesis was

only observed in FDBA and not in DFDBA group.

Conclusion:

Our study results showed that we can move the teeth into a defect filled with DFDBA or FDBA. It was also demonstrated that biomaterial graft does not damage the root and bone reaction around it will be normal. Therefore, we can consider these allografts as an alternative for autogenous bone graft for moving the tooth into the bone defects.

References:

1. Kavamoto T, Motohashi N, Kitamura A, Baba Y, Takahashi K, Suzuki S: A histological study on experimental tooth movement into bone induced by recombinant human bone morphogenetic protein-2 in beagle dogs. *Cleft Palate Craniofac J* 2002;39:439-448
2. Oltramari PV, de Lima Navarro R, Henriques JF, Taga R, Cestari TM, Ceolin DS, Granjeiro JM: Orthodontic movement in bone defects filled with xenogenic graft: An experimental study in minipigs. *Am J Orthod Dentofacial Orthop* 2007;131:302.e10-17
3. Feinberg SE, Weisbrode SE, Heintschel G: Radiographic and histological analysis of tooth eruption through calcium phosphate ceramics in the cat. *Arch Oral Biol* 1989;46:975-984
4. Hossain MZ, Kyomen S, Tanne K: Biologic responses of autogenous bone and beta tricalcium phosphate ceramics transplanted into bone defects to orthodontic forces. *Cleft Palate Craniofac J* 1996;33:276-283
5. Araújo MG, Carmagnola D, Berglundh T, Thilander B, Lindhe J: Orthodontic movement in bone defects augmented with Bio-Oss An experimental study in dogs . *J Clin Periodontol* 2001; 28: 73-80
6. Yukna RA, Vastardis S: Comparative evaluation of decalcified and non-decalcified freeze-dried bone allografts in rhesus monkeys. *J Periodontol* 2005;76:57-65.
7. Rosen PS, Reynolds MA, Bowers GM. The treatment of intrabony defects with bone grafts. *Periodontol* 2000;22:88-103
8. Mellonig JT, Bowers GM, Bailey RC: Comparison of bone graft materials. Part I. New bone formation with autografts and allografts determined by Strontium-85. *J Periodontol* 1981;52:291-296
9. Piattelli A, Scarano A, Corigliano M, Piattelli M: Comparison of bone regeneration with the use of mineralized and demineralized freeze-dried bone allografts: A histological and histochemical study in man. *Biomaterials* 1996;17:1127-1131
10. Rummelhart JM, Mellonig JT, Gray JL, Towle HJ: A comparison of freeze-dried bone allograft and demineralized freeze-dried bone allograft in human periodontal osseous defects. *J Periodontol* 1989;60:655-663

Suggestion:

Further investigations on a larger sample size, sacrificing the samples at different time intervals and also creating larger defects by extracting one of the posterior teeth are recommended.

Acknowledgement:

This article was originally the doctoral thesis of Meysam Mirzaee. The instructing professor was Dr. Masoud Seifi from Shahid Beheshti University of Medical Sciences, School of Dentistry.

11. Newman M, Takei H, Kokkevoold P, Carranza F. Clinical periodontology .10th Ed. St.Louis: MO:Saunders 2006:976-982
12. Anderegg CR, Martin SJ, Gray JL, Mellonig JT, Gher ME. Clinical evaluation of the use of decalcified freeze-dried bone allograft with guided tissue regeneration in the treatment of molar furcation invasions. J Periodontol 1991;62:264-8.
13. Cammack G 2nd, Nevins M, Clem DS 3rd, Hatch JP: Histologic evaluation of mineralized and demineralized freeze dried bone allograft for ridge and sinus augmentations. Int J Periodontics Restorative Dent 2005;25:231-237
14. Wennström JL, Stokland BL, Nyman S, Thilander B: Periodontal tissue response to orthodontic movement of teeth with infrabony pockets. Am J Orthod Dentofacial Orthop 1993;103:313-319.
15. Brezniak N, Wasserstein A :Orthodontically induced inflammatory root resorption. Part II: The clinical aspects. Angle Orthod 2002;72:180-184.