

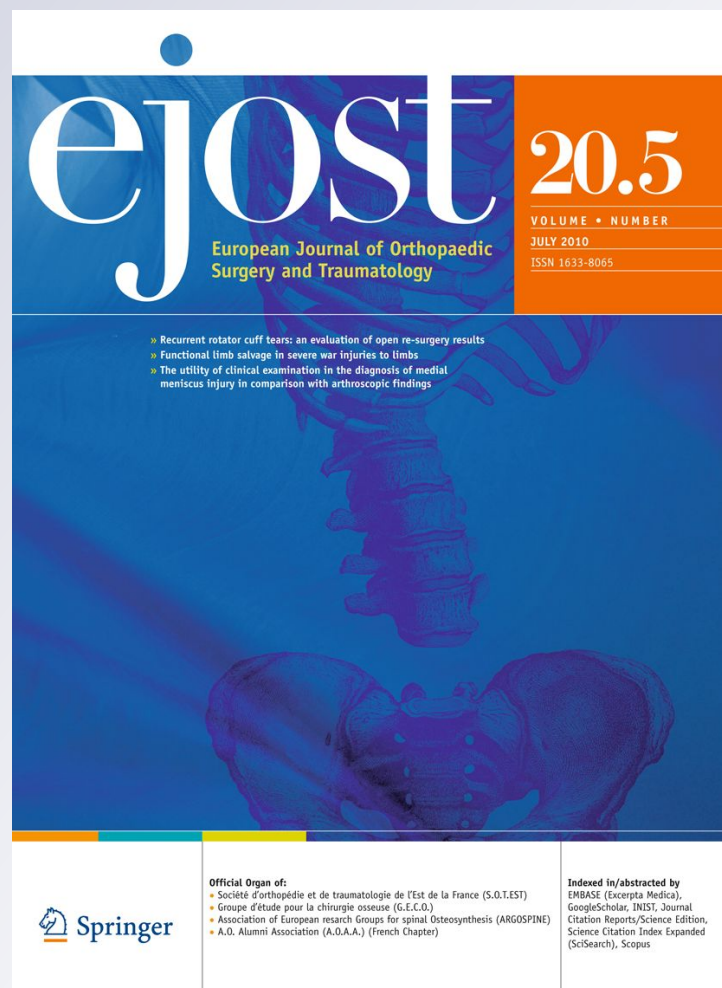# *Opening wedge high tibial osteotomy using tibial wedge allograft: a case series study*

**Reza Ganji, Maryam Omidvar, Alireza Izadfar & Seyed Mohammad Alavinia**

**European Journal of Orthopaedic Surgery & Traumatology**

ISSN 1633-8065

Eur J Orthop Surg Traumatol  
DOI 10.1007/s00590-011-0933-4



**Your article is protected by copyright and all rights are held exclusively by Springer-Verlag. This e-offprint is for personal use only and shall not be self-archived in electronic repositories. If you wish to self-archive your work, please use the accepted author's version for posting to your own website or your institution's repository. You may further deposit the accepted author's version on a funder's repository at a funder's request, provided it is not made publicly available until 12 months after publication.**

## Opening wedge high tibial osteotomy using tibial wedge allograft: a case series study

Reza Ganji · Maryam Omidvar · Alireza Izadfar ·  
Seyed Mohammad Alavinia

Received: 20 November 2011 / Accepted: 20 December 2011  
© Springer-Verlag 2012

**Abstract** High tibial osteotomy has been established as an effective surgical intervention in patients with uni-compartment osteoarthritis of the knee associated with varus deformity and abnormal load through the medial compartment. The aims of this study were to report the result of open-wedge osteotomy performed with allograft bone and also to evaluate the postoperative clinical results in a series of patients. There are still little medical literatures regarding the use of an allograft bone transplant in open-wedge osteotomy. 37 consecutive cases that had undergone opening wedge osteotomy using allograft bone were studied. They were followed each 2 months after surgery until 6 month. There were 7 men and 30 women, aged ranging from 16 to 66. All patients were followed 6 months after surgery until clinical and radiographic healing of the osteotomy site. All patients could stand and walk on operated limb 6 months after operation, but 11 of them had still pain after this duration. There were no cases of non-union or osteotomy site collapse associated with the use of allograft. Moreover, no significant complication has been detected in these patients with choosing appropriate patients and performing good surgical technique, and the

proximal tibial wedge allograft is a satisfactory choice that provides effective clinical and radiographic bone union.

**Keywords** High tibial osteotomy · Allograft · Osteoarthritis

### Introduction

Unicompartment osteoarthritis of the knee is associated with varus deformity and abnormal load through the medial compartment. An osteotomy for the proximal aspect of the tibia can correct the abnormal loading stresses on the knee caused by an altered femorotibial angle. High tibial osteotomy has been established as an effective surgical intervention in these patients and for unloading the medial compartment after cartilage restoration that could improve quality of life and cause high patients satisfaction rate [1–3].

In surgical procedure of the medial compartment, good long-term results depend on the ultimate correction, which is ideally 2–8 degree of valgus of the tibiofemoral angle [2, 4]. There are two known surgical methods for this procedure. The first one is the lateral closing wedge osteotomy of the proximal tibia that provides a stable construct for earlier weight-bearing and bone union; however, problem related to fibular osteotomy, disruption of the tibiofibular joint, detachment of the extensor muscle, proneal nerve injuries, and shortening of the limb have been reported with this procedure [2, 5]. Today medial opening wedge as the second type of the procedure is becoming more popular because it is simpler and avoids these problems [6, 7]. It can be combined with an anterior cruciate ligament reconstruction through the same incision and has lengthening effect. Despite these benefits, longer union time and

---

R. Ganji · A. Izadfar  
Imam Ali Hospital, Bojnourd, Iran

M. Omidvar  
Genetic Epidemiology, Tehran, Iran

S. M. Alavinia  
Department of Social Medicine, Medical School, Northern  
Khorasan University of Medical Sciences, Bojnourd, Iran

S. M. Alavinia (✉)  
P.O. Box: 13185-1678, Tehran, Iran  
e-mail: swt\_f@yahoo.com

need for the bone graft are associated with this method. Patients' selection, surgical technique, type of fixation, use of supplement for fixation, and the choice of material or bone graft to fill the osteotomy defect are the important factors that are related to these complications [8]. With regard to the use of bone graft, autogenous iliac crest has been the preferred graft because of its structural characteristics [9]. Autogenous bone graft harvest from the iliac crest has been associated with morbidity and potential complications such as deep wound infection, gluteal artery injury, and sciatic nerve injury [7, 10–16]. The use of an allograft bone wedge could eliminate these problems. There are still little medical literatures regarding the use of an allograft bone transplant in open-wedge osteotomy.

The aim of this study was to report the result of open-wedge osteotomy performed with allograft bone. We also aimed to evaluate the postoperative clinical results in a series of patients.

## Materials and methods

### Cases

We studied 37 consecutive cases that had undergone opening wedge osteotomy using allograft bone between July 11, 2006, and November 18, 2009. We also followed these patients prospectively each 2 months after surgery until 6 month. There were 7 men and 30 women, aged ranging from 16 to 66. None of patients had bi- or tri-compartmental arthritis, inflammatory disease, BMI > 40, or joint line obliquity more than 10°. We also excluded patients with insulin-dependent diabetes mellitus, heavy cigarette smoking, and exogenous steroid use. All patients were followed 6 months after surgery until clinical and radiographic healing of the osteotomy site.

### Clinical and radiographic assessment

The surgeon performed clinical and radiographic evaluation of each patient. Preoperative measurement obtained from full-length standing radiograph that gives a correct estimation of axial alignment of lower extremity. Follow-up was done each 2 months from the operation time to evaluate the radiographic and clinical improvement. The clinical indicators used to assess union were complaint of pain as well as sign of tenderness, warmth, and swelling at the osteotomy site. We also measured pain score in each follow-up based on visual analogue scale (VAS).

Radiographic examinations involved anteroposterior (AP) and lateral view of the osteotomy site. Indicators used to assess bony union were bone bridging across the osteotomy site and disappearance of osteotomy line on serial

examinations. Non-union was consider for patients when above indicators were absent after 6 months.

### Surgical technique

Our goal was to obtain a tibiofemoral valgus angle of 6°–8° or angle between mechanical axis of femur and tibia near 0. We used classic operation technique [7], but in our procedure, tibial shaft allograft was chosen to fill the osteotomy defect.

Cortico-cancellus freeze-dried allograft prepared by tissue regeneration corporation (processed in a sterile calss1000 environment by using low-level gamma irradiation below 2.5 Megarad). The surgeon shaped it in operation room to a desirable size to precisely fill the osteotomy defect (Fig. 1a, b, c).

Fixation of osteotomy with T-plate and screws was done. The knee protected in a brace that permits a full range of motion. Partial weight-bearing allowed immediately and full weight-bearing allowed when we had X-ray finding of bone union or the patient could tolerate it.

### Statistical analysis

For the main variable, we generated descriptive statistics such as mean and percentages. Pearson's correlation coefficient was used to find the relationship between different variables and pain improvement. All analyses were carried out with the statistical package SPSS version 18.

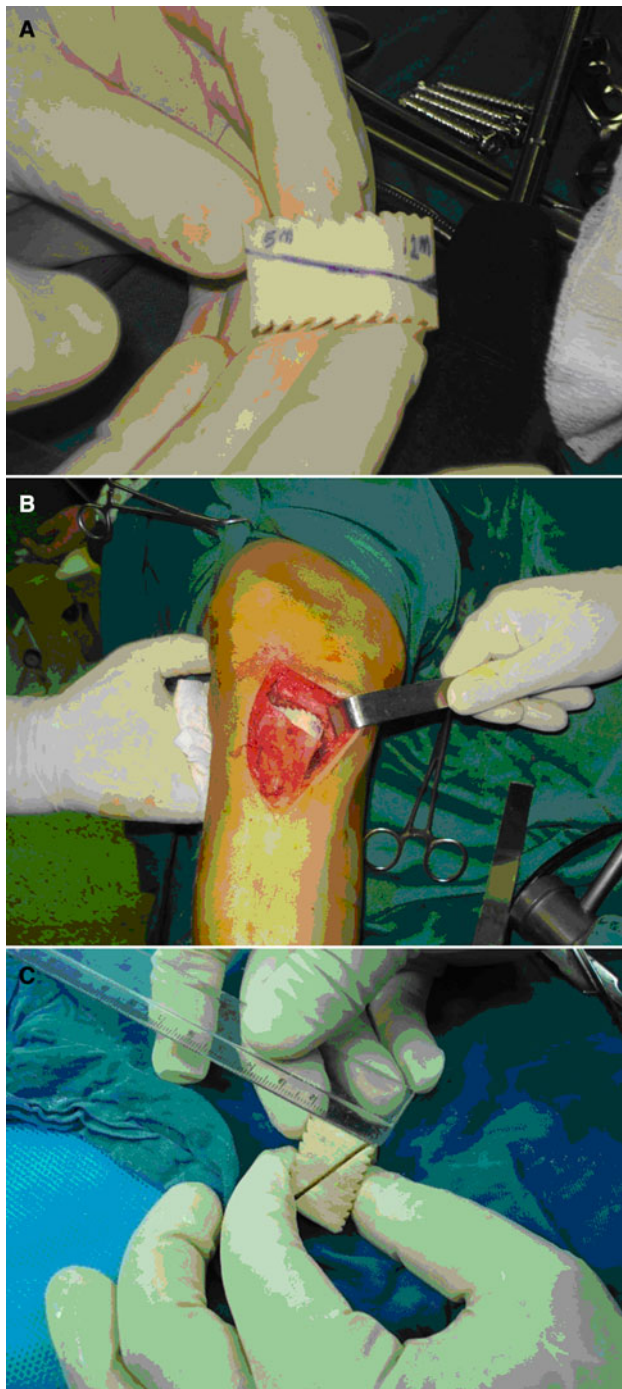
## Results

Table 1 shows basic characteristics of the study population. Most of the patients were women (81.1%). The mean BMI among patients was 28.28 (SD = 5.20).

Table 2 shows pre- and post-operation tibiofemoral angle. All of the patients had more than 5 degree varus before operation. Since the favorable degree after surgery is 0–6 degree valgus, we categorize the different degree of this angle based on the best correction after surgery. Among all the patients who undergone surgery 20 (54.1%) have the best correction of this angle. Although we measured severe varus in some patients before surgery, none of them remain varus after the operation.

Table 3 shows bony bridge formation, ability of patients for standing on operated limb, and pain in the operated site in different follow-up times. All patients could stand and walk on operated limb 6 months after operation, but 11 of them had still pain after this duration. There were no cases of non-union or osteotomy site collapse associated with the use of allograft. Moreover, no significant complication has been detected in these patients. There was a negative





**Fig. 1** Open-wedge osteotomy technique

correlation between age of the patients and improvement of pain.

**Discussion**

We found that using allograft in open-wedge osteotomy would be a satisfactory method in the treatment of patients

**Table 1** Baseline characteristics of 37 patients who underwent open-wedge osteotomy

|                          | N  | Mean ± SD    |
|--------------------------|----|--------------|
| Age                      | 37 | 44 ± 13.55   |
| Female (%)               | 30 | 81.1%        |
| BMI category             |    |              |
| Normal                   | 11 | 29.7%        |
| Overweight               | 15 | 40.5%        |
| Obese                    | 11 | 29.7%        |
| Operation duration (min) | 37 | 88.78 ± 1.99 |

**Table 2** Tibiofemoral degree pre- and post-operation in 37 patients underwent open-wedge osteotomy

|                                  | Post-operation tibiofemoral angle |            |          |
|----------------------------------|-----------------------------------|------------|----------|
|                                  | <0                                | 0–6        | >6       |
| Pre-operation tibiofemoral angle |                                   |            |          |
| –20 to –15                       | 5 (31.3%)                         | 5 (25%)    | 0 (0%)   |
| –15 to –10                       | 4 (25.0%)                         | 6 (30.0%)  | 1 (100%) |
| –10 to –5                        | 5 (31.3%)                         | 9 (45%)    | 0 (0%)   |
| >–5                              | 2 (12.5%)                         | 0 (0%)     | 0 (0%)   |
| Total                            | 16 (43.2%)                        | 20 (54.1%) | 1 (2.7%) |

**Table 3** Formation of bone bridge, stand on the operation limb and pain in first, second, third, and fourth follow-up in 37 patients

|                  | Bone bridge formation | Stand on operated limb | Still pain |
|------------------|-----------------------|------------------------|------------|
| Firs follow-up   | 1 (2.7%)              | 5 (13.5%)              | 36 (97.3%) |
| Second follow-up | 14 (37.8%)            | 26 (70.3%)             | 32 (86.5%) |
| Third follow-up  | 31 (34%)              | 34 (91.9%)             | 19 (51.4%) |
| Fourth follow-up | 35 (94.6%)            | 37 (100.0%)            | 11 (29.7%) |

with unicompartment osteoarthritis of the knee. Complete clinical and radiographic improvement occurred within 6 month. The lower incidence of non-union and other complication in addition of the long-term graft integrity in our study group would support the use of this graft over synthetic substitutes.

Previous report has suggested that bone allograft is suitable substitute for autograft [8]. Although some reports have suggested that synthetic graft accompanied with appropriate union without important complications [17], these synthetic grafts have not good availability in our country. Moreover, other advantages should be taken into account such as low cost, easy preparation and implantation at surgery, less complication and ability to shape the allograft bone in operation room.

In line with other authors, we also believe that one of the most important factors in using this procedure and using

bone allograft is proper patient selection [2, 9, 18]. The factors that have effect on bone healing should be considered. Therefore, patients aged over 65 years, smokers, exogenous steroid users, and bone mass index more than 40 are not appropriate for this procedure [8]. We also believed that this graft compares favorably to the result obtained with autogenous iliac crest graft. In this procedure, the cancellous portion of allograft acts as an ideal osteoconductive substitute in this situation [8].

One limitation of our study was the lack of a comparison group. There was no possibility to compare these patients with other patients who undergone other technique or other material for open-wedge surgery. It should be also mentioned that in this study the clinical and radiographic assessment of bone union during follow-up period and subjective and objective evaluation of complications were performed by a single examiner who had done the surgery.

In conclusion, with choosing appropriate patients, and good surgical technique, the proximal tibial wedge allograft is a satisfactory choice that provides effective clinical and radiographical bone union.

**Acknowledgments** The authors would like to thank Farzan Institute for Research and Technology for technical assistance.

**Conflict of interest** Authors declare any conflicts of interests.

## References

- Bauer GC, Insall J, Koshino T (1969) Tibial osteotomy in gonarthrosis (osteo-arthritis of the knee). *J Bone Joint Surg Am* 51:1545–1563
- Coventry MB, Ilstrup DM, Wallrichs SL (1993) Proximal tibial osteotomy. A critical long-term study of eighty-seven cases. *J Bone Joint Surg Am* 75:196–201
- Tang WC, Henderson IJ (2005) High tibial osteotomy: long term survival analysis and patients' perspective. *Knee* 12:410–413
- Valenti JR, Calvo R, Lopez R, Cañadell J (1990) Long term evaluation of high tibial valgus osteotomy. *Int Orthop* 14:347–349
- Hernigou P, Ma W (2001) Open wedge tibial osteotomy with acrylic bone cement as bone substitute. *Knee* 8:103–110
- Magyar G, Toksvig-Larsen S, Lindstrand A (1998) Open wedge tibial osteotomy by callus distraction in gonarthrosis. Operative technique and early results in 36 patients. *Acta Orthop Scand* 69:147–151
- Prix R (2005) Opening-wedge osteotomy of the proximal tibia. *Acta Chir Orthop Traumatol Cech* 72:308–312
- Yacobucci GN, Cocking MR (2008) Union of medial opening-wedge high tibial osteotomy using a corticocancellous proximal tibial wedge allograft. *Am J Sports Med* 36:713–719
- Noyes FR, Mayfield W, Barber-Westin SD, Albright JC, Heckmann TP (2006) Opening wedge high tibial osteotomy: an operative technique and rehabilitation program to decrease complications and promote early union and function. *Am J Sports Med* 34:1262–1273
- Amendola A, Bonasia DE (2010) Results of high tibial osteotomy: review of the literature. *Int Orthop* 34:155–160
- Brull SJ, Lieponis JV, Murphy MJ, Garcia R, Silverman DG (1992) Acute and long-term benefits of iliac crest donor site perfusion with local anesthetics. *Anesth Analg* 74:145–147
- Esenkaya I, Elmali N (2006) Proximal tibia medial open-wedge osteotomy using plates with wedges: early results in 58 cases. *Knee Surg Sports Traumatol Arthrosc* 14:955–961
- Heary RF, Schlenk RP, Sacchieri TA, Barone D, Brotea C (2002) Persistent iliac crest donor site pain: independent outcome assessment. *Neurosurgery* 50:510–516
- Todd BD, Reed SC (1991) The use of bupivacaine to relieve pain at iliac graft donor sites. *Int Orthop* 15:53–55
- Warden SJ, Morris HG, Crossley KM, Brukner PD, Bennell KL (2005) Delayed- and non-union following opening wedge high tibial osteotomy: surgeons' results from 182 completed cases. *Knee Surg Sports Traumatol Arthrosc* 13:34–37
- Wilkes RA, Thomas WG (1994) Bupivacaine infusion for iliac crest donor sites. *J Bone Joint Surg Br* 76:503
- Koshino T, Murase T, Saito T (2003) Medial opening-wedge high tibial osteotomy with use of porous hydroxyapatite to treat medial compartment osteoarthritis of the knee. *J Bone Joint Surg Am* 85-A:78–85
- Staubli AE, De Simoni C, Babst R, Lobenhoffer P (2003) TomoFix: a new LCP-concept for open wedge osteotomy of the medial proximal tibia—early results in 92 cases. *Injury* 34(Suppl 2):B55–B62